

Broken Bones and Blind Eyes: Ocular and Orbital Injuries in Craniofacial Trauma

TAYYABA GUL MALIK¹, MUHAMMAD KHALIL¹, KHALID FAROOQ²

ABSTRACT

Aim: To describe ocular, neuro-ophthalmological and imaging patterns of head trauma, with special reference to road traffic accidents (RTA) in an urban area of Pakistan.

Study Design: Descriptive, retrospective study.

Study period: 2007 to 2013

Subjects and settings: 42 Patients of cranio facial trauma from three different centers of Lahore were included in the study. History charts and neuro-imaging reports were reviewed. The data considered for the study was age, sex, ocular manifestations, neuro-ophthalmological findings and imaging reports

Results: Male to female ratio was 6:1. Craniofacial injuries were common in patients of ≤ 40 years of age. The commonest cause of trauma was road traffic accidents (RTA). 9 patients had severe vision loss (NPL= no perception of light). 50% patients (n=21) had left sided trauma. 5(11.9%) were normal with no clinical and neuro-imaging findings. Congested eyes, decreased vision, muscle entrapment in orbital fracture and restricted extra ocular movements due to severe edema were common ocular findings. Other clinical signs were Enophthalmos, Hyphema, intra ocular foreign body, ocular motor nerve palsies, papilledema, retinal detachment, ruptured globe, traumatic optic neuropathy, vitreous hemorrhage, Carotico-cavernous fistula and chiasmal damage.

Conclusion: In urban areas, RTA account for maximum ocular injuries secondary to craniofacial trauma. Proper and prompt actions in emergency department by multidisciplinary experts can not only save lives but also vision.

Keywords: Orbital wall fractures, blow out fractures of the orbit, road traffic accidents,

INTRODUCTION

There are seven bones of face and skull, that constitute an orbit; (frontal, sphenoid, zygomatic, maxilla, ethmoid, lacrimal, and palatine). Optic nerve exits at the orbital apex and hence it can be damaged in orbital injuries. Orbital rims are relatively strong but the walls of orbit, especially medial wall and floor are thin and are more prone to be knocked out in craniofacial assaults and accidents.

This paper reviews cases of face and skull trauma, which result in ocular and orbital injuries, either by direct or indirect blow. Owing to the hike in road traffic accidents and poor law enforcement in Pakistan, special consideration is given to the ocular and neu-ophthalmic injuries in RTA.

SUBJECTS AND METHODS

It was a descriptive retrospective study. 42 patients with craniofacial trauma were selected (from three different centers). We reviewed clinical and imaging

charts of these patients. Clinical data included history, visual acuity, color vision, pupillary reactions, extra ocular movements, intra ocular pressures, field of vision, slit lamp examination and fundoscopy. In severely injured and unconscious patients, we were not able to measure vision, tonometry, slit lamp examination and extra ocular movements. Other specific tests were pulsations, bruit and exophthalmometry (where and when necessary).

Computerized tomography with both plain and post contrast images were studied for fractures. Images were observed on both soft tissue and bone window settings (subject to availability). In some patients, MRI with T2 and T1 weighted plain and post contrast images were also available. Gd-DTPA was utilized for post contrast component. Data was compiled, results deduced and descriptive statistical analysis was done.

RESULTS

Forty-two patients, 36 males and 6 females (male: female ratio, 6:1) were included in the study. Age ranged from 2 years to 75 years (mean 38.5 years). 36 patients were ≤ 40 years and 6 patients were more than 40 years (Graph 1).

The commonest cause of trauma was RTA 32(76.2%). Other causes were; fall from height

¹Associate Professor of Ophthalmology, Lahore Medical and Dental College Lahore

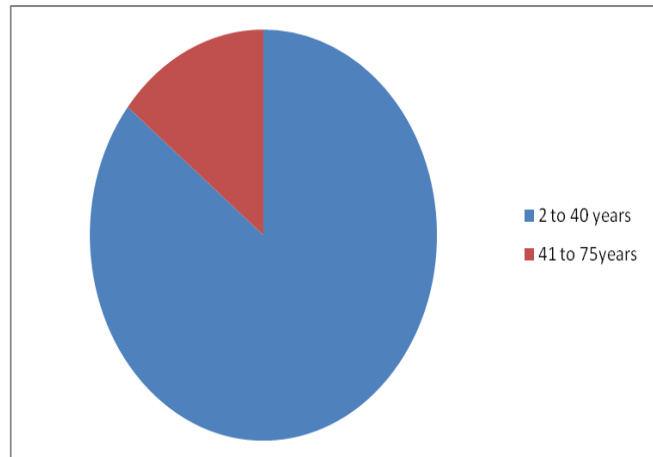
²Professor, Department of radiology, Lahore Medical and Dental College Lahore

Correspondence to Dr. Tayyaba Gul Malik, Associate Professor
E.mail:tayyabam@yahoo.com, Mob: 0300-4217998

5(11.9%), face blow 3(7.1%) and gunshot injuries 2(4.8%). Accurate measurement of visual acuity was not possible, either because of serious nature of injuries or non availability of proper visual acuity assessment tools in emergency ward. The patients were divided into three categories with respect to rough estimate of vision. Those with normal vision (8 patients, who could identify different objects in the ward), those with decreased vision (n=25), and patients who could not perceive light (NPL= no perception of light, n=9). 21(50%) patients had left sided trauma. Bilateral and right sided involvement was seen in 8(19.04%) each. 5(11.9%) were normal with no clinical and neuro-imaging findings. The common ocular findings in our series were congested eyes, restricted extra ocular movements either because of edema or muscle entrapment in fractures of orbital walls. 15(35.7%) patients had neuro-ophthalmic signs, which included traumatic optic neuropathy (n=9), Papilledema (n=2), ocular motor nerve palsies (n=2), Chiasmatal damage (n=1) and direct carotico- cavernous fistula (n=1). 30 patients had normal pupils. 10 had either relevant afferent pupillary defect or total afferent pupillary defect and two patients had papilledema. For details of ocular and neuro-ophthalmic picture, refer to graph 3.

Computerized tomography (CT scan) and Magnetic resonance imaging (MRI) results were analyzed. Multiple fractures were more common in our series of patients 15(35.7%). 26.19% (n=11/42) cases had single orbital wall fracture. Out of these 11, 45.45% (n=5/11) patients had orbital floor fracture. Orbital roof fracture was the next commonest of single wall fractures (n=4/11, 36.36%).

Fracture of the lateral orbital rim was seen in 11.9% (n= 5/42) patients. For details, refer to graph 4.



Graph 1: Cranio-facial trauma in different age groups.

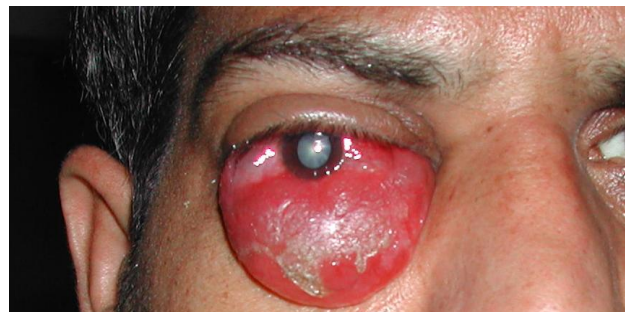

Fig. 1: Post traumatic Carotico-Cavernous fistula in a patient with road traffic accident

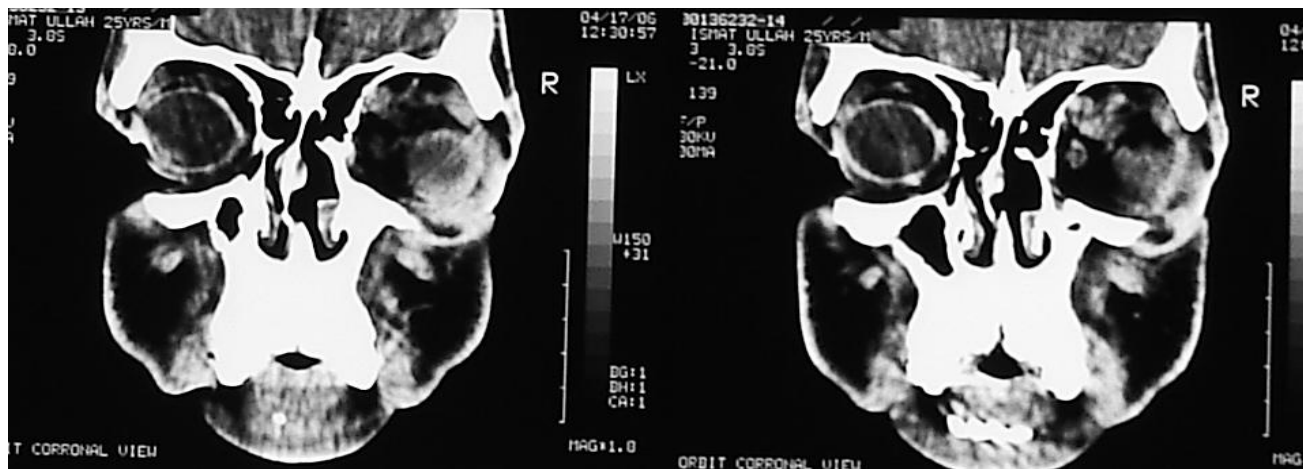
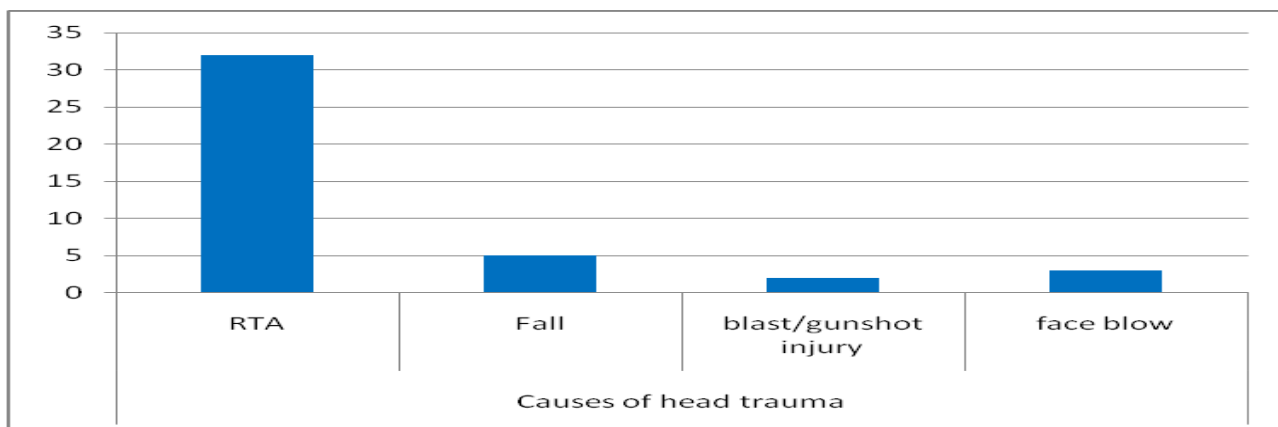
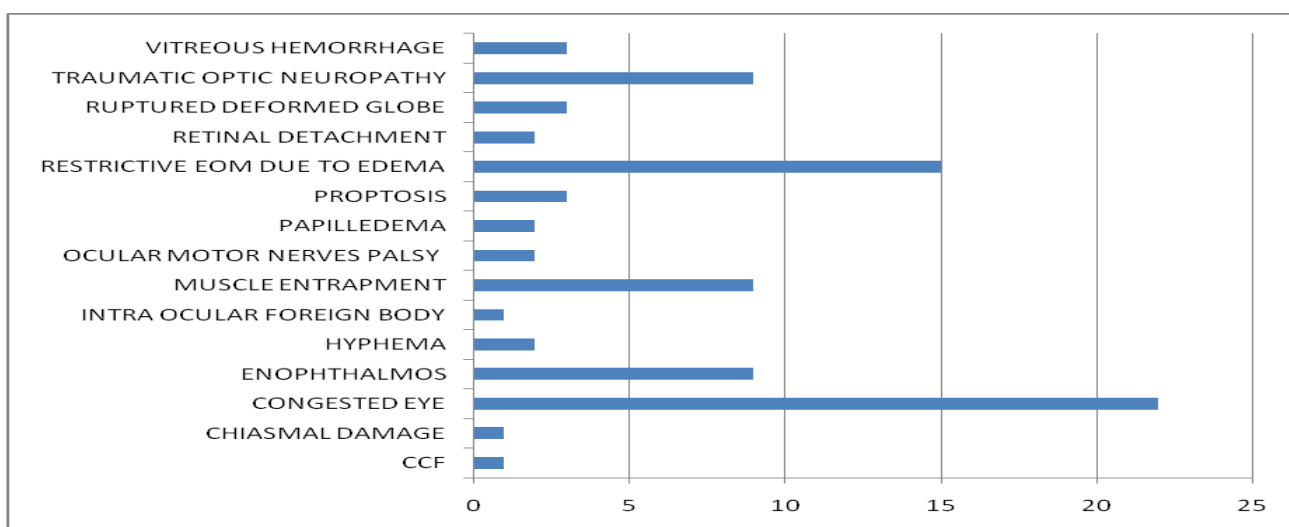


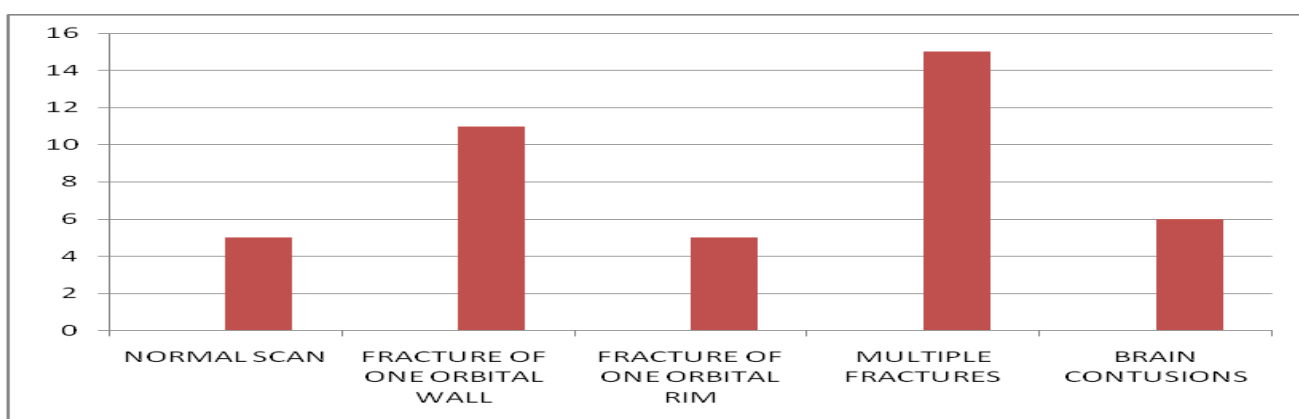
Fig. 2: CT scan showing multiple fractures of the orbital walls with swollen extra ocular muscle of right eye. Herniation of orbital contents into maxillary sinus can also be seen.



Graph 2: Causes of cranio-facial trauma



Graph 3: Ocular and neuro-ophthalmic findings in patients of cranio-facial trauma



Graph 4: Details of neuro-imaging reports (CT scan and MRI)

DISCUSSION

Nature has housed eyeball in a bony pyramidal shaped orbit for its protection. Bony rims are strong enough to combat trauma, but medial and inferior walls are weaker and are usually damaged by a direct or indirect blow to head or face. When injuries of such severity occur, eyeballs are also affected. This particular study highlights the ocular, orbital and neuro-ophthalmic injuries in head and facial traumas. RTA was the commonest cause of such injuries in our study (76.2%). However, in earlier studies in Khaybar pakhtoon kha and Balochistan this percentage was 2.2% and 6.5% respectively^{1,2}. In these provinces, occupational hazards were more common than RTA. According to World Health Organization, more than 1.2 million lives are lost to RTA across the globe³ and Pakistan is 5th leading contributor to deaths due to RTA worldwide with an estimated 41494 deaths per year⁴. In India, RTA account for 52.5% to 70.37 % of head injuries^{5,6}. In other parts of the world, RTA was again the leading cause of cranio facial trauma^{7,8,9}. A Korean study showed occupational accidents to be more common than RTA¹⁰ (similar to Balochistan and KPK, Pakistan).

It is a well known fact that male to female ratio is universally high for head injuries^{6,7,11,12}. In this particular study it was 6:1. This ratio was 4:1 in Balochistan and almost similar in KPK^{1,2} in earlier studies.

Surprisingly, we had more percentage of left sided trauma in RTA (50% cases). It was contrary to Libyan study, in which 42% patients had right sided trauma¹³. This difference could be due to different driving patterns. In Pakistan, it is left side driving while in Libya driving is right side, so the injuries are more common on the left and right side respectively. The common ocular findings in our series were congested eyes, Enophthalmos, restricted extra ocular movements either because of edema or muscle entrapment in fractures of orbital walls. According to a study by Kulkarni and Agarwal, sub conjunctival hemorrhage and ecchymosis were the commonest ocular findings in head injuries⁵. Globe avulsion is a very rare complication of head trauma and only few case reports of globe avulsion are available in literature¹⁴. There was no such patient in our series.

To check accurate visual acuity in the settings of emergency department is not an easy task. Studies have shown that it is not a good predictor of severity of ocular and orbital injury¹⁵. Although we had 9 patients who had no perception of light, there were many visually asymptomatic cases with very critical orbital wall fractures and vice versa.

In this particular study, 15(35.7%) patients had neuro-ophthalmic signs. Commonest neuro-ophthalmic finding was post traumatic optic neuropathy. Van Stavern GP showed a higher percentage (56.7%) of neuro-ophthalmic deficits in head injuries¹⁶. While ocular motor nerve palsies were common in other studies¹⁷. We had two patients of lateral rectus palsy. One of the patients had superior and inferior orbital margin fractures while the other patient had normal CT and MRI scans and no obvious cause of lateral rectus palsy was found. Only few case reports are available in literature, which show post traumatic lateral rectus palsy with normal radiographic findings¹⁸. Another study indicated that location of the imaging abnormalities did not correlate with a particular cranial nerve injury¹⁹. To highlight the cause of post-traumatic cranial nerve palsies, Mariak Z carried out brain biopsy in 12 patients who had died from head injuries. In the majority of cases damage resulted from ripping the roots out of the brainstem but he found no visible injury to the optic nerves²⁰. Other studies indicated that moderate to severe brain injuries were closely related to ocular motor nerve palsies²¹.

Importance of pupil examination in cranio facial injuries cannot be overlooked. Bilateral fixed dilated or pinpointed fixed pupils had ten times more risk of mortality than those without pupil involvement⁶. 30 patients in our study had normal pupils. 10 patients had either relevant afferent pupillary defect or total afferent pupillary defect. Two patients had papilledema. According to ACS Committee on Trauma, the initial sign of Temporal herniation is ipsilateral miosis, which occurs secondary to third nerve irritation. This is referred to as Hutchison's stage I. In Hutchison's stage II, there is paralysis of third nerve which leads to ipsilateral pupillary dilatation²². Bilateral fixed dilated pupils and Glasgow coma Scale 3 are the signs of severe brain injury²³. Pupillary reactions are normal in cortical blindness. None of our patients had cortical blindness while it was reported in 0.4–0.6% patients of Banks et al²⁴.

For diagnosis, management and follow up of fractures of face and skull, CT scan is very important. We had only six patients whose follow up scans were available. Five of them had successful repair of orbital floor fractures. Only one (2.4%) patient in our series had intra ocular foreign body. It was a piece of broken glass from windscreen. In earlier RTA reports glass fragments were the commonest cause of penetrating eye injuries²⁵. It is therefore recommended that use of seat belts should be made compulsory not only by law making but by law enforcement.

CONCLUSION

In urban areas, RTA account for maximum ocular injuries secondary to craniofacial trauma but serious trauma can be minimized by proper law enforcement. In the emergency wards, pupil examination is more important than visual acuity tests. Proper and prompt actions in emergency department by multidisciplinary experts can not only save lives but also vision.

REFERENCES

1. Khan MD, Muhammad S. An 11½ years review of Ocular. Trauma in NWFP of Pakistan. *Pak. J Ophthalmol.* 1991; 7: 15-8.
2. Shahwani MA, Hameed K, Jamali B. Ocular Injuries: Its Etiology and Consequences in Balochistan. *Pak J Ophthalmol* 2006;(2): 82-84
3. Peden M. World report on road traffic injury prevention. Geneva: World Health Organization; 2004.
4. World Health Organization, Regional Office for the Eastern Mediterranean: Eastern Mediterranean status report on road safety: call for action. Cairo: WHO/EMRO; 2010.
5. A R Kulkarni AR, Aggarwal SP, Kulkarni RR, Deshpande MD, Walimbe PB, Labhsetwar AS. Ocular manifestations of head injury: a clinical study. *Eye.* 2005; 19:1257–1263
6. Sharma B, Gupta R, Anand R, Ingle R. Ocular manifestations of head injury and incidence of post-traumatic ocular motor nerve involvement in cases of head injury: a clinical review. *Int Ophthalmol.* 2014; 34(4):893-900.
7. Ehsaei MR, Heidari M, Karimiani EG, Ehsaei A. Ophthalmic complications among cases of head trauma in north-eastern Iran. *Int Ophthalmol.* 2014; 34(4):825-9.
8. Odebode TO. Age related pattern and outcome of head injury in indigenous Africa. *Niger J Clin Pract.* 2008; 11(3):265-9.
9. Eze KC, Enock ME, Eluehike SU. Ultrasonic evaluation of orbito-ocular trauma in Benin-City, Nigeria. *Niger Postgrad Med J.* 2009;16(3):198-202.
10. Oum BS, Lee JS, Han YS. Clinical features of ocular trauma in emergency department. *Korean J Ophthalmol.* 2004;18(1):70-8.
11. Bener A, Rahman YS, Mitra B. Incidence and severity of head and neck injuries in victims of road traffic crashes: In an economically developed country. *Int Emerg Nurs.* 2009;17(1):52-9.
12. Oner A, Kecec Z, Karakucuk S, Ikizceli I, Sözüer EM. Ocular trauma in Turkey: a 2-year prospective study. *Adv Ther.* 2006;23(2):274-83.
13. Shtewi ME, Shishko MN, Purohit GK. Road Traffic Accidents and Ocular Trauma: Experience at Tripoli Eye Hospital, Libya. *Community Eye Health.* 1999; 12(29): 11–12.
14. Santos TS, Vajgel A, Ribeiro CF, de Santana Júnior JR, Andrade ES. Avulsion of globe following maxillofacial trauma. *J Craniofac Surg.* 2012;23(4): 1097-100.
15. Mellema PA, Dewan MA, Lee MS, Smith SD, Harrison AR. Incidence of ocular injury in visually asymptomatic orbital fractures. *Ophthal Plast Reconstr Surg.* 2009 25(4):306-8.
16. Van Stavern GP, Biousse V, Lynn MJ, Simon DJ, Newman NJ. Neuro-ophthalmic manifestations of head trauma. *J Neuroophthalmol.* 2001;21(2):112-7.
17. Odebode TO, Ademola-Popoola DS, Ojo TA, Ayanniyi AA. Ocular and visual complications of head injury. *Eye (Lond).* 2005;19(5):561-6.
18. Czyz CN, Harder JD, Cahill KV, Kuennen RA, Foster JA. Isolated bilateral abducens nerve palsy without radiographic etiology and unique mechanism of injury. *Orbit.* 2011;30(5):239-41
19. Dhaliwal A, West AL, Trobe JD, Musch DC.J. Third, fourth, and sixth cranial nerve palsies following closed head injury. *Neuroophthalmol.* 2006;26(1):4-10.
20. Mariak Z, Stankiewicz A. Cranial nerve II-VII injuries in fatal closed head trauma. *Eur J Ophthalmol.* 1997; 7(1):68-72.
21. Ventura RE, Balcer LJ, Galetta SL. The neuro-ophthalmology of head trauma. *The Lancet Neurology.* 2014;13(10): 1006-1016.
22. ACS Committee on Trauma. Advanced Trauma Life Support Course for Physicians, 3rd edn. Student Manual, American College of Surgeons: Chicago, 1993.
23. Cheung PS, Lam JM, Yeung JH, Graham CA, Rainer TH. Outcome of traumatic extradural haematoma in Hong Kong. *Injury.* 2007;38(1):76-80.
24. Banks M, Lessell, Simmons MD. Neuro-ophthalmology and Trauma. *Int Ophthalmol Clin Ocular Trauma* 2002; 42(3): 1–12.
25. Panagiotidis DN, Theodossiadis PG, Petsias CB, Kyriaki TE, Marakis TP, Friberg TR, Moschos MN. Ocular injuries secondary to motor vehicle accidents. *Eur J Ophthalmol.* 2004;14(2):144-8.